

Large Optic Disks in the Marshallese Population

James M. Maisel, M.D., Caryn S. Pearlstein, M.D., William H. Adams, M.D.,
and Peter M. Heotis, M.P.S.

On routine examination, asymptomatic patients from the Marshall Islands were noted to have large optic disks associated with high cup/disk ratios and normal intraocular pressure. We retrospectively analyzed color fundus photographs of 54 eyes and 22 eyes of 15 patients had optic disks greater than 2.10 mm, or megalopapilla. Of 36 patients with cup/disk ratios exceeding 0.6, 31 (86%) had visual acuities of better than or equal to 20/30. The optic nerve rim and disk areas varied directly as did disk and cup diameters. Three large disks with an 18-year photographic follow-up showed no change. Optic disk characteristics can vary widely among genetically isolated populations.

DURING ROUTINE ophthalmologic examination of a Micronesian population in the Republic of the Marshall Islands, a striking number of patients were noted to have large optic disks. These disks were associated with high cup/disk ratios without increased intraocular pressures, other disk anomalies, or any other ocular complaints.¹ This Pacific atoll population, which may be considered genetically isolated, demonstrates a large number of people with megalopapilla.

Fundus photographs were obtained on a group of patients noted to have high cup/disk ratios as well as on a randomly selected group of control patients. We performed a masked

retrospective analysis of the fundus photographs in order to demonstrate that the optic disks that appeared on ophthalmoscopic examination to have high cup/disk ratios were actually larger than those optic disks judged clinically normal on ophthalmoscopy.

Subjects and Methods

The population examined consisted of 141 adults native to the Marshall Islands. Some had a history of radiation exposure in 1954, and it is to provide diagnosis and care of radiation-related illness that complete physical examinations are performed annually.² However, many unexposed patients are also examined. All examinees receive ophthalmologic evaluation, including slit-lamp examination, biennially. Visual acuities are measured with a Snellen chart at 20 feet. For this study there was no selection based on age, sex, previous radiation exposure, consanguinity, or ocular complaints or findings. The ocular examination was performed by an ophthalmologist (J.M.M.) who was part of the Brookhaven National Laboratory medical team. He completed a standardized examination form for each patient as well as performed the fundus photography. All patients thought to have abnormally large disks or high cup/disk ratios underwent fundus photography, as did many patients with normal disks who served as controls. Fundus photographs were taken in a total of 63 patients. The photographs were given to a masked observer (C.S.P.) for analysis.

Color slides of the optic nerve head taken with a fundus camera were projected onto the screen of a slide viewer. Using a ruler, measurements were made directly from the projected image. Black and white photographs of the optic disks of three patients were available from 1967, and measurements made directly from these photographs were compared to those of 1985.

Accepted for publication Oct. 14, 1988.

From the Department of Ophthalmology, School of Medicine, State University of New York at Stony Brook, Stony Brook, New York (Drs. Maisel and Pearlstein) and the Medical Department, Brookhaven National Laboratories, Upton, New York (Drs. Adams and Heotis).

This project was supported in part by the U.S. Department of Energy under Contract No. DE-AC02-76CH00016. Accordingly, the U.S. Government retains a nonexclusive, royalty-free license to publish or reproduce the published form of this contribution or allow others to do so for U.S. Government purposes.

Reprint requests to James M. Maisel, M.D., 400 S. Oyster Bay Rd., Suite 305, Hicksville, NY 11801-3516.

Measurements of the horizontal and vertical disk diameters were made carefully, excluding peripapillary halos and crescents. Horizontal and vertical cup diameters were estimated by color contrast taking into account changes in vessel direction at the cup edge as an indication of cup contour change where possible. The diameter of the largest vein on the disk edge was measured before it joined the central retinal vein. Finally, measurements of the superior, inferior, nasal, and temporal disk rim widths were made. Horizontal and vertical disk diameters were compared and then the two dimensions were combined to generate an average disk diameter which was used for further calculations and comparisons.

For 21 optic nerve heads, two to three slides of each nerve were available. In these cases, measurements were made from each slide and an average of the measurements was obtained.

In order to minimize the magnification or minification of the photographic image caused by the eyes' axial length, refractive power, and the camera optics, the actual disk and cup diameters were calculated by determining the ratio of the structure to that of a vein on the disk and multiplying by 125 μm , its actual size.³ This method assumes that the vein on the disk will be subject to the same optical enhancement or reduction as the disk.

Actual diameter structure = $125 \mu\text{m} \times \text{measured structure/measured disk vein}$

Cup/disk ratios were calculated by dividing the cup diameter by that of the disk. To calculate the neural rim area, the horizontal and vertical disk and cup diameters were averaged and the areas for each were calculated using the following formula:

$$\text{Area of a circle} = \pi(\text{diameter}/2)^2$$

The cup area (C) was subtracted from the disk area (D) to yield the rim area (R).

The presence or absence of glaucomatous features such as disk asymmetry, vertical disk cupping, and notching of the neural rim were assessed.

Correlations between disk diameter, cup diameter, rim area, and cup/disk ratio vs history of radiation exposure, visual acuity, and intraocular pressure were studied.

Results

Acceptable photographs were available for 54 eyes of 36 patients. There were 15 men (42%) and 21 women (58%). They ranged in age from 30 to 67 years, with a mean \pm S.D. age of 44.1 ± 11.3 years for the men and 43.5 ± 10.2 years for the women. Of the 36 patients, 19 (53%) had a history of radiation exposure. Only two pairs of subjects were known to be related. The first pair, a mother and a son, had relatively large disk diameters of 1.8 mm and 2.1 mm, respectively, in their right eyes. The mother had a cup/disk ratio of 0.5, whereas her son with a larger disk had a cup/disk ratio of 0.7. The second pair of related individuals were sisters. Each had disk diameters of 1.65 mm and cup/disk ratios of 0.4 in their left eyes. Information on the fellow eyes in both pairs of individuals was not available. Although there were similarities in disk size and cup/disk ratios between each of these related individuals, no firm conclusions concerning heredity can be drawn given such a small sample size.

The optic disk—Franceschetti and Bock⁴ calculated the mean \pm S.D. optic disk diameter of a normal Swiss population to be 1.62 ± 0.153 mm. In those eyes with oval disks, they averaged the vertical and horizontal measurements, as was done in this study. They reasoned that since only 0.26% of the observations in a normal distribution would be expected to exceed three standard deviations from the mean, which corresponded to 2.08 mm in their study, megalopapilla could be defined as a disk diameter greater than 2.08 mm.⁵

Because photographs were taken mainly of large optic disks with some normal disks for comparison, the distribution in our study would naturally be skewed. Therefore, a disk diameter greater than or equal to 2.1 mm was adopted from Franceschetti and Bock's study as the criterion for a large optic disk. The average disk diameter in this study population was 1.93 ± 0.28 mm (Fig. 1).

Of 54 eyes, 22 had optic disks with a diameter greater than or equal to 2.1 mm. Fifteen of 36 patients had large optic disks, the condition being bilateral in seven patients and unilateral in eight. Examples of large optic disks are shown in Figure 2.

Cup/disk ratio—In the Framingham Eye Study, the average cup/disk ratio was 0.28 ± 0.17 and two standard deviations above the

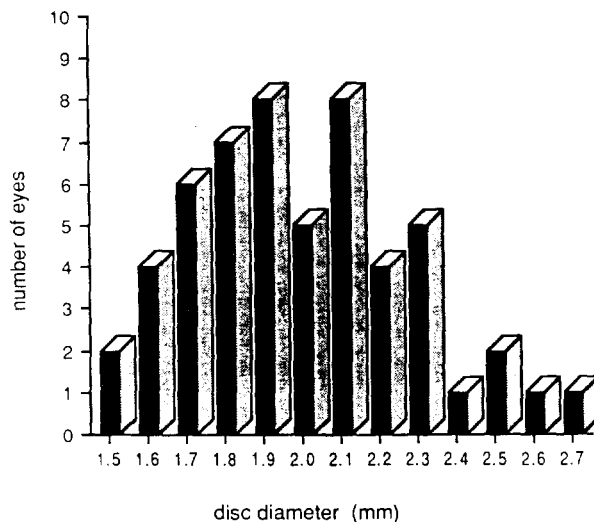


Fig. 1 (Maisel and associates). Disk diameter plotted against number of eyes. Quantitative analysis of patients selected for photographs demonstrates 22 eyes with megalopapilla with average disk diameters greater than or equal to 2.1 mm.

mean was equal to 0.62.⁶ Because two or more standard deviations above the mean accounted for only 7.5% of their study population, 0.6 or more was accepted as the criterion for a large cup/disk ratio in our study.⁵ This criterion is in agreement with Syndacker's work⁷ in which he concluded that optic disks with physiologic cupping exceeding 0.66 occur so infrequently that it is to be considered pathologic until proven otherwise.

Such physiologic cupping as defined above was found in 20 of 22 eyes (91%) with large optic disks, but in only eight of 32 eyes (25%) with small disks. When cup vs disk diameter was plotted, the two variables were found to be linearly related (Fig. 3).

Rim area—When rim area was plotted against disk area, it was found that in this study population, rim and disk areas vary directly (Fig. 4).

Radiation exposure—Of the 36 patients, 19 had a history of accidental exposure to external whole-body radiation during atmospheric nuclear testing in 1954. Nine patients from the Rongelap atoll received an estimated 1.75 Gy (175 rad) and the ten patients from the island of Utirik received approximately 0.14 Gy (14 rad).²

Of the 36 patients in this study, 19 (a group different from the 19 above) had acceptable photographs of both eyes: 12 of these 19 had been exposed to radiation, five had not, and in two the data were not available. A comparison of the disk sizes in the 12 exposed and five nonexposed patients demonstrates that the two groups have relatively the same proportion of patients with large disks (Table 1).

Evidence of glaucoma—Features considered to be consistent with glaucomatous optic disk damage other than cupping, such as notching of the neural rim, disk asymmetry, vertical disk cupping, and increased intraocular pressure were investigated. Examination of the neural rim of the optic disk showed 360 degrees of pink neural tissue without notching in all cases. In the 19 patients for whom data were available on both eyes, two had asymmetric

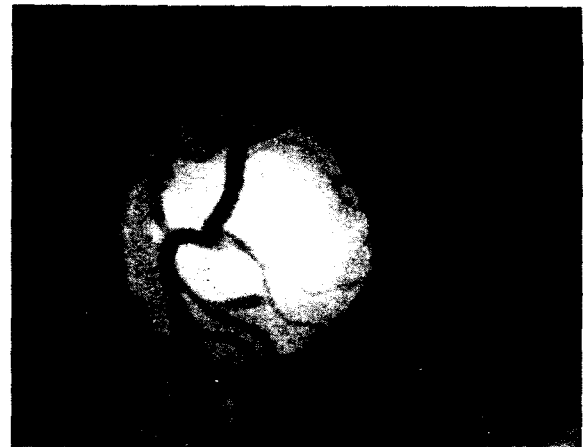

Fig. 2 (Maisel and associates). Example of bilateral megalopapilla. Left, Right disk diameter of 2.3 mm. Right, Left disk diameter of 2.2 mm.

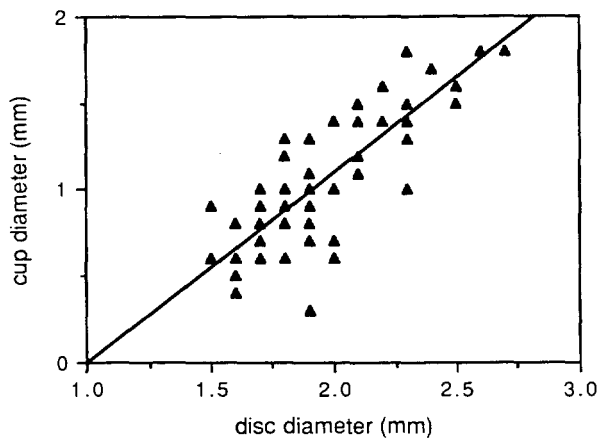


Fig. 3 (Maisel and associates). Cup diameter plotted against disk diameter showing that large disks tend to have large cups.

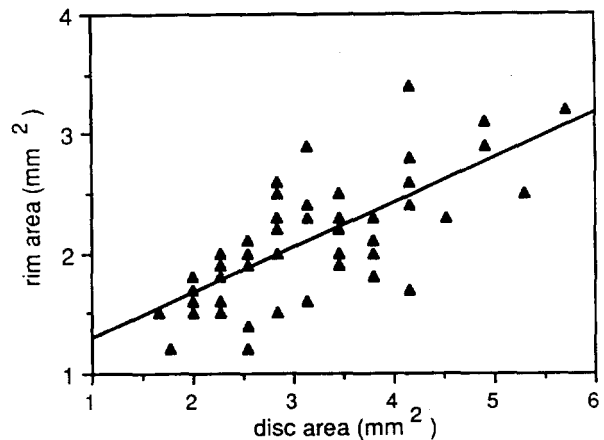


Fig. 4 (Maisel and associates). Rim area plotted against disk area showing that large disks tend to have greater rim area.

disks. These two patients had differences in their cup/disk ratios equal to 0.2, with no other stigmata of glaucoma. Disk asymmetry, that is, disks whose cup/disk ratios differ by more than 0.2, was found by Armaly to represent only 0.5% of the normal population.⁸

Vertical disk cupping where the vertical cup diameter exceeds that of the horizontal was found in 17 of 54 eyes. In each case, the vertical measurement did not exceed that of the horizontal by more than 0.01 mm, a difference which would probably go unnoticed when observed through an ophthalmoscope.

The average \pm S.D. intraocular pressure was calculated after grouping the eyes into four categories. Eyes with large disks and large cups had an intraocular pressure of 11.8 ± 1.8 mm Hg; those with small disks and small cups, 11.4 ± 1.6 mm Hg; those with small disks and large cups, 11.5 ± 2.3 mm Hg; and those with large disks and small cups, 12.5 ± 2.5 mm Hg. There was no significant difference between the groups.

Visual acuity—Of the 36 patients, 31 (86%) had visual acuities better than or equal to 20/30

and 23 (64%) saw 20/20 or better. Of the five patients with visual acuities less than 20/30, three had reduced vision attributed to cataract. As a result of congenital nystagmus plus bilateral pigment mottling in the macula from previous toxoplasmosis, the fourth patient had a visual acuity of 20/50. The fifth patient had an uncorrected visual acuity of 20/200, which improved with pinhole to 20/40, in both eyes. However, no visual acuity was recorded on the chart following refraction with a -2.50 sphere.

Long-term follow-up—Optic disk photographs taken in 1967, 18 years before this study, were available for three patients (Table 2). There was essentially no change in either disk or cup diameters over the 18-year period.

Discussion

In this genetically isolated population in the Marshall Islands, 15 patients were found to

TABLE 1
RADIATION EXPOSURE AND OPTIC DISK SIZE

DISK SIZE (MM)	EXPOSED (N=12)	NONEXPOSED (N=5)
Bilateral >2.1	6	2
Bilateral <2.1	5	2
Unilateral >2.1	1	1

TABLE 2
COMPARISON OF OPTIC DISKS AFTER 18 YEARS OF FOLLOW-UP

PATIENT NO.	1967		1985	
	DISK DIAMETER (MM)	CUP/DISK RATIO	DISK DIAMETER (MM)	CUP/DISK RATIO
1	2.2	0.90	2.1	0.75
2	2.2	0.70	2.2	0.70
3	1.7	0.70	1.8	0.70

have optic disk diameters that fell beyond two standard deviations above the mean of a normal white population. In most cases, physiologic cups were also large, resulting in pale disks because of the increased visibility of the lamina cribrosa. Each case was associated with a full, sharp rim of healthy pink neural tissue without evidence of glaucomatous damage and with good visual acuity. The 18-year follow-up in three patients showed no change suggestive of an acquired, progressive process.

The definition of megalopapilla is based on the distribution of optic disk sizes in a normal white population, but may not be applicable to all racial groups. Neither the exact prevalence of megalopapilla nor the mean optic disk or cup diameters in the Marshall Island population could be calculated because fundus photographs were taken mainly of patients with large disks and high cup/disk ratios with several normal disks for comparison. The nonrandom nature of this study would skew the distribution of disk and cup sizes toward the larger end of the spectrum. However, the finding of 15 cases of megalopapilla, which is equal to the number previously reported, is certainly significant.⁹ This is not without precedent. In a study of uric acid levels in the Marshallese, it was concluded that the observed increases in serum uric acid levels were not restricted to a subset of persons with hyperuricemia. Instead, the distribution of uric acid levels throughout the entire population tested was gaussian, suggesting a mean value and normal range of uric acid that is approximately 1.0 mg/dl higher than that found in the United States. Since "hyperuricemia" is common throughout the Pacific, it is possible that megalopapilla also occurs with increased prevalence in the Marshall Islands.¹⁰

Another question is whether radiation exposure plays a role in these differences. In our study of megalopapilla, the small sample size precludes drawing conclusions based on statistical significance; however, since both exposed and nonexposed groups have relatively the same proportion of patients with large disks, it is unlikely that radiation exposure was a factor contributing to the formation of such. Additionally, the presence of a unilaterally large disk cannot easily be explained by whole-body radiation exposure.

The effect of age and sex on disk and cup size must also be addressed. Although most authors agree that the cup size probably does not vary appreciably with sex, there is some con-

trovery as to whether it increases with age.^{7,8} Two studies have found no change in cup size with increasing age,^{11,12} whereas the Framingham Eye Study,⁶ Pickard,¹³ and Carpel and Engstrom¹⁴ all found a slight increase in cup size with age. However, because age did not cause the cup/disk ratios to exceed 0.6 in these last three studies, we could not attribute our 20 cases (out of 54) of cup/disk ratios greater than 0.6 to age alone, if at all. For these reasons, the effect of age and sex on cup and disk sizes was not considered to be significant for this study.

Another interesting finding concerned the rim area. A study by Teal, Marin, and McCulloch¹⁵ showed that although cup area increased with disk area, rim area remained constant, suggesting that in large disks, cups enlarged so as to keep the rim area and hence the amount of neural tissue the same from person to person. In contrast, our study showed that as disk and cup area increased, rim area increased as well. Although cup area increased with disk area enough to raise the cup/disk ratio, disk size seemed to be increased out of proportion to the physiologic cup, yielding a larger rim area than expected. Recent work^{11,16} confirms our findings that disk and rim areas vary directly. Whether this larger rim area results from an increase in neural tissue or an increase in extraneuronal supporting tissue is uncertain.

In 1985 a study showed that blacks tend to have significantly larger cup/disk ratios than whites (0.35 mm for blacks and 0.24 mm for whites).¹⁷ However, the investigators did not evaluate the disk size or rim area. It would be of interest to know whether physiologic cupping in blacks is associated with larger disks and if these disks contain a greater amount of neural or extraneuronal tissue. Conversely, disk size may not vary at all from that of the white population, thus leading to a situation where there is a smaller but adequate amount of neural or extraneuronal tissue. In either case, the amount of neural tissue becomes important when considering neuronal reserve under pathologic conditions such as glaucoma or compressive mass lesions that lead to optic atrophy.

Racial differences in disk and cup sizes are consistent with both Armaly's⁸ and Bengtsson's¹⁸ studies, which showed that cup and disk sizes are genetically determined. Although there were similarities in disk size and cup/disk ratios between two pairs of related individuals in this study, no firm conclusions

concerning heredity could be drawn. However, taken as a whole, within this genetically isolated population, it is not surprising to have found optic disk sizes and cup/disk ratios that are different from our usual white reference population.

Faced with a pale disk accompanied by a large cup/disk ratio, other signs and symptoms indicative of an optic disk abnormality are usually searched for. It is reasonable from this study to conclude that in addition to signs and symptoms such as decreasing visual acuity, visual field defects, pupil abnormalities, increased intraocular pressure, poor color vision, and defects in the peripapillary nerve fiber layer and the neural rim, one should also take into account the racial or ethnic background of the patient before determining that the disk is abnormal. Furthermore, given the variability in optic disk size, measurements of rim area may prove more useful when assessing neuronal loss than measurements of the cup/disk ratio.

References

1. Brown, G., and Tasman, W.: Congenital Anomalies of the Optic Disc. New York, Grune and Stratton, 1983, pp. 207-212.
2. Conrad, R. A.: Late radiation effects in Marshall Islanders exposed to fallout 28 years ago. In Boice, J. D., Jr., and Fraumeni, J. F., Jr. (eds.): Radiation Carcinogenesis. Epidemiology and Biological Significance. New York, Raven Press, 1984, p. 57.
3. Collins, J. F.: Handbook of Clinical Ophthalmology. New York, Masson Publishing USA, Inc., 1982, p. 714.
4. Franceschetti, A., and Bock, R. H.: Megalopapilla. A new congenital anomaly. Am. J. Ophthalmol. 33:227, 1950.
5. Kuzma, J. W.: Basic Statistics for the Health Sciences. Mountain View, California, Mayfield Publishing Co., 1984, p. 67.
6. Kahn, H. A., Leibowitz, H. M., Ganley, J. P., Kini, M. M., Colton, T., Nickerson, R. S., and Dawber, T. R.: The Framingham eye study, Am. J. Epidemiol. 106:17, 1977.
7. Syndacker, D.: The normal optic disc. Am. J. Ophthalmol. 58:958, 1964.
8. Armaly, M. F.: Genetic determination of cup/disc ratio of the optic nerve. Arch. Ophthalmol. 78:35, 1967.
9. Miller, N. R.: Walsh and Hoyt's Clinical Neuro-Ophthalmology, ed. 4. Baltimore, Williams and Wilkins, 1982, vol. 1, p. 343.
10. Adams, W. H., Harper, J. A., Heotis, P. M., and Janner, A. H.: Hyperuricemia in the inhabitants of the Marshall Islands. Arthritis Rheum. 27:6, 1984.
11. Britton, R. J., Drance, S. M., Schulzer, M., Douglas, G. R., and Mawson, D. K.: The area of the neuroretinal rim of the optic nerve in normal eyes. Am. J. Ophthalmol. 103:497, 1987.
12. Airaksinen, P. J., Drance, S. M., and Schulzer, M.: Neuroretinal rim area in early glaucoma. Am. J. Ophthalmol. 99:1, 1985.
13. Pickard, R.: The alteration in size of the normal optic disc and cup. Br. J. Ophthalmol. 32:355, 1948.
14. Cappel, E. P., and Engstrom, P. F.: The normal cup/disc ratio. Am. J. Ophthalmol. 91:588, 1981.
15. Teal, P. K., Marin, J. D., and McCulloch, C.: Assessment of the normal disc. Trans. Am. Ophthalmol. Soc. 52:165, 1972.
16. Caprioli, J., and Miller, J. M.: Optic disc rim area is related to disc size in normal subjects. Arch. Ophthalmol. 105:1683, 1987.
17. Beck, R. W., Messner, D. K., Musch, D. C., Maronyi, C. L., and Lichter, P. R.: Is there a racial difference in physiologic cup size? Ophthalmology 92:873, 1985.
18. Bengtsson, B.: The inheritance and development of cup and disc diameters. Acta Ophthalmol. 58:733, 1980.

REPOSITORY BNL RECORDS
 COLLECTION MARSHALL ISLANDS
 BOX NO. MEDICAL DEPT. PUBLICATIONS
 FOLDER UNLABELED

The Medical Research Center
 Brookhaven National Laboratory
 Upton, L. I., New York

5012526